

Research article

Intrathecal transplantation of autologous adipose-derived mesenchymal stem cells for treating spinal cord injury: A human trial

Junseok W. Hur, Tai-Hyoung Cho, Dong-Hyuk Park, Jang-Bo Lee, Jung-Yul Park, Yong-Gu Chung

Department of Neurosurgery, Korea University College of Medicine, Korea University Anam Hospital, Seoul, Republic of Korea

Context: Spinal cord injury (SCI) can cause irreversible damage to neural tissues. However, there is currently no effective treatment for SCI. The therapeutic potential of adipose-derived mesenchymal stem cells (ADMSCs) has been emerged.

Objective: We evaluated the effects and safety of the intrathecal transplantation of autologous ADMSCs in patients with SCI.

Participants/Interventions: Fourteen patients with SCI were enrolled (12 for ASIA A, 1 for B, and 1 for D; duration of impairments 3–28 months). Six patients were injured at cervical, 1 at cervico-thoracic, 6 at thoracic, and 1 at lumbar level. Autologous ADMSCs were isolated from lipoaspirates of patients' subcutaneous fat tissue and 9×10^7 ADMSCs per patient were administered intrathecally through lumbar tapping. MRI, hematological parameters, electrophysiology studies, and ASIA motor/sensory scores were assessed before and after transplantation.

Results: ASIA motor scores were improved in 5 patients at 8 months follow-up (1–2 grades at some myotomes). Voluntary anal contraction improvement was seen in 2 patients. ASIA sensory score recovery was seen in 10, although degeneration was seen in 1. In somatosensory evoked potential test, one patient showed median nerve improvement. There was no interval change of MRI between baseline and 8 months post-transplantation. Four adverse events were observed in three patients: urinary tract infection, headache, nausea, and vomiting.

Conclusions: Over the 8 months of follow-up, intrathecal transplantation of autologous ADMSCs for SCI was free of serious adverse events, and several patients showed mild improvements in neurological function. Patient selection, dosage, and delivery method of ADMSCs should be investigated further.

Keywords: Adipose tissue, Autologous, Intrathecal, Mesenchymal stem cells, Spinal cord injury, Transplantation

Introduction

Spinal cord injury (SCI) generally results from physical insult, caused by traumatic events. According to the degree of neural tissue damage, the effects of SCI are various grades of irreversible disability in motor and sensory functions. The number of people in the United States living with SCI in 2013 was estimated to be ~273,000 and the numbers continue to increase.¹

Methylprednisolone is the only agent that has been shown to be effective for SCI reducing axonal damage

from secondary injury process.^{2–4} However, several shortcomings, such as the 8-hour therapeutic window, the moderate efficacy, and the high risk of complications bring into question the value of such early high-dose steroid use, and so this is not a satisfactory treatment for SCI.⁵

The continuing need for more effective and safer treatment has resulted in the search for therapeutic strategies that target the restorative stage over the acute narrow therapeutic window, such as cell-based therapies designed to regenerate damaged cells and simultaneously provide anti-inflammatory and/or neurotrophic factors to prevent the secondary neurodegeneration inherent in SCI. Stem cell transplantation

Correspondence to: Tai-Hyoung Cho, Department of Neurosurgery, Korea University College of Medicine, Korea University Anam Hospital, #126, 5-Ga, Anam-Dong, Sungbuk-Ku, Seoul, 136-705, Korea.
Email: choth2@korea.ac.kr

is a promising and attractive cell-based treatment modality for repairing the damaged central nervous system, including in SCI. Many studies have successfully used stem cell-based therapy in animal models of SCI and have achieved some degree of functional recovery.^{6,7}

Among the various types of stem cell, the availability of adult stem cells as a source for cell transplantation is of particular interest. Unlike embryonal or fetal-origin stem cells, using adult stem cells has fewer ethical and/or moral problems, as well as lower teratogenic and oncogenic risks. Bone-marrow-derived mesenchymal stem cells (MSCs) have been investigated in animal model studies and, furthermore, several clinical studies in patients have been reported.^{8–13} In contrast, because of its recent discovery, adipose-tissue-derived mesenchymal stem cells (ADMSCs) are still poorly investigated in many fields though it is anticipated to have various advantages. Some groups have focused on the potential of ADMSCs as a graft source for neurodegenerative diseases such as stroke.^{14–16} However, SCI has received little attention as a target disease for stem cell therapy using ADMSCs.

Recently, however, some studies used ADMSCs for animal models of SCI and reported good results.^{17–19} Zhou *et al.*¹⁹ investigated whether human ADMSCs transplanted into a rat model of SCI would lead to similar or improved neurologic effects compared with human bone marrow-derived MSCs. They concluded that human ADMSCs would be more appropriate for transplant to treat SCI than human bone marrow-derived MSCs. Menezes *et al.*²⁰ focused on pro-regenerative effects of ADMSCs. They investigated the regenerative properties of human ADMSCs in a rat model of spinal cord compression. As laminin (well-known inducer of axonal growth, as well as a component of the extracellular matrix associated with neural progenitors) of human origin at the lesion site and spinal midline was shown, they propose that it can be the paracrine factor mediating the pro-regenerative effects of human ADMSCs in SCI. On the other hand, Zhao *et al.*¹ claimed that a population of neuronal cells can be specifically generated from ADMSCs and the induced cells may allow for participation in tissue repair. They succeed in culturing ADMSCs for neurogenic differentiation and observed neurogenic cell colonization in injured mouse spinal cord at the site of transplantation. But, to the best to our knowledge, there have so far been no human clinical trials of administrating ADMSCs to patients with SCI via any mechanism. In this study, we evaluate the effects and safety of the intrathecal transplantation of autologous ADMSCs in patients with SCI, which would be the first attempt in this field.

Methods

This phase I study of autologous ADMSC intrathecal therapy for SCI was approved by the Korean Food and Drug Administration (Investigational New Drug Application no. 201005033) and the Korea University Anam Hospital (Seoul, Korea) Institutional Review Board (No. ED 11144). This clinical trial started on Aug 8, 2011 and was completed on June 24, 2013. Written informed consent was obtained from each participant.

Patient selection

Candidates were given information regarding the expected efficacy and safety of the trial, based on results from preclinical tests, in which the SCI model animals showed improved motor function with human adipose stem cells and few adverse effects.^{17–19}

The inclusion criteria were patients with neurological impairment due to SCI, aged 19–69 years. The patients underwent the best treatments available for SCI for at least 3 months before joining this clinical trial. Two individual neurologists, respectively, examined the patients twice over a 4-week interval to ensure there were no changes in neurological status during interval. Exclusion criteria included ventilator-assisted breathing, history of malignancy within the past 5 years, concomitant infectious diseases, such as HIV or HBV infection, anemia, myocardial infarction, occlusive vascular disease, chronic renal failure, fever above 38°C, mental confusion or dysphasia, use of immunosuppressants, corticosteroids, or cytotoxic agents, or another serious pre-existing medical condition.

ADMSC isolation and culture

Autologous ADMSCs were isolated from lipoaspirates of subcutaneous fat tissue obtained from the enrolled participants. A liposuction procedure was performed by T-H Cho, the principal investigator, under sterile conditions in the operating room at Korea University Anam Hospital. Lipoaspiration was taken from abdomen and/or thigh. Under lidocaine local anesthesia, injection cannula was inserted at subcutaneous fat layer and 50–60 mL of tumescent solution (normal saline 100 cc + lidocaine 25 cc + epinephrine 1 cc) was injected. After 10–15 minutes, aspiration cannula was inserted and 10–20 mL of fat tissue was aspirated. Then, the lipoaspirates were delivered to Anterogen Co., Ltd. and were washed at least three times with phosphate-buffered saline (PBS) and digested in an equal volume of PBS containing 1% bovine serum albumin and 0.025% collagenase type I (Invitrogen, Gaithersburg, MD) for 80 min at 37 °C with

intermittent shaking. Isolated cells were cultured for three weeks in Dulbecco's modified Eagle's medium (DMEM; Invitrogen), supplemented with 10% fetal bovine serum (FBS; Hyclone, Logan, UT) and 1 ng/mL human basic fibroblast growth factor (bFGF), and used at passage 3 (about 21 days of culture). Cells were stocked and preserved at -196°C in the middle of production and further cultured in order to meet the schedule of injections. BSA and FBS were washed out for the final product according to FDA guidelines ('Points to consider in the characterization of cell lines used to produce Biologicals', 1993). Quality-control tests, including cell viability, and fungal, bacterial, endotoxin, and mycoplasma contamination, were carried out by Anterogen Co. Ltd and confirmed by investigators before cell delivery. For lot release testing, the cells were assayed for quality control parameters, such as viability ($\geq 80.0\%$), cell morphology identification (observation of adherent cells with spindle-shaped morphology), cell surface protein identification using flow cytometry ($\geq 80.0\%$ in CD90+/CD45- cells), purity ($< 1.0\%$ in CD45+ cells), and negative microbial contamination testing. Cells were stable for 24 hours at $5\text{--}20^{\circ}\text{C}$. Autologous ADMSCs were prepared at 3×10^7 autologous cells per 1-mL DMEM and, in total, 9×10^7 cells were delivered to cold storage (-4°C) without a cryopreservation procedure and administered within 1 hour.

Intrathecal transplantation of autologous ADMSCs

Referring to previous studies,^{21–23} three 1-mL DMEM aliquots containing 3×10^7 autologous cells/each were prepared and in total 9×10^7 autologous ADMSCs per patient were administered on day 1, at 1 month, and at 2 months respectively into the intrathecal space over 5 minutes through lumbar spinal tapping.

Rehabilitation program

We did not provide any specific rehabilitation program to ensure the effect of stem cell transplantation. The patients only maintained their regular activity routines.

Neurological scales

Before transplantation at baseline and then at 1, 2, 4, 6 and 8 months after final transplantation (2 months after first transplantation), neurological examinations were performed by J-B Lee, a senior spine expert, using the American Spinal Injury Association (ASIA) motor and sensory scores.

Physical examinations and vital sign assessments

Throughout the entire study period, we performed physical examinations and vital sign assessments for every single visit. We also checked any drug use in combination with the transplants, and any adverse effects that patients complained about.

Laboratory, radiological studies

Before the lipoaspiration operation, patients were assessed in terms of hematology, blood chemistry, and urine analysis, and were screened for HIV, HBV/HCV, and VDRL. A chest X-ray, pulmonary function test, and spinal magnetic resonance imaging (MRI) were performed. T1/T2 weighted axial and sagittal MRI (Achieva 3.0 T; Philips, Best, The Netherlands) were obtained. Two neuroradiologists, who were not included in the study, described the MRI as a formal reading. All these studies were performed again at 8 months after final transplantation.

Electrophysiological studies

Electrophysiological examinations of motor and sensory function, such as electromyography (EMG), motor evoked potential (MEP), and somatosensory evoked potentials (SSEP) were performed before and after transplantation (same schedule as radiologic studies). Sierra Wave (Cadwell, Kennewick, WA, USA) was used for neurophysiologic examination. Nerve conduction and needle EMG were performed. For nerve conduction, median and ulnar nerve were studied for upper limbs' motor/sensory. Tibial and peroneal nerves were studied for motor conduction, and sural and superficial peroneal nerves were studied for sensory conduction. The SSEP was elicited by median nerve stimulation and tibial stimulation. Three to four series were obtained during every test. MEP were elicited by transcranial magnetic stimulation using MagPro (Medtronic, Shoreview, MN, USA) of primary motor cortex and recorded in contralateral abductor pollicis brevis (APB) muscle.

Results

Within a given period of time, 21 patients applied to participate for the study and only 14 patients (12 males, 2 females) qualified for the inclusion criteria. Their ages were 20–66 years (mean \pm SD = 41.9 ± 15.5 years). The minimum time between the impairment and study inclusion was 3 months (mean \pm SD = 13.7 ± 7.6 months). Thirteen patients were injured as a result of traffic accident-related trauma or falls. One patient was impaired due to myelitis. There were six cervical injuries, one cervico-thoracic, six thoracic, and one

Table 1 Patients' characteristics

	Sex	Age (years)	Injury level	Cause of impairment	Injury degree	ASIA grade	Duration of impairment (months)	Follow up duration (months)
Patient 1	M	66	T12	Trauma	Complete	A	8	8
Patient 2	M	42	T12	Trauma	Complete	A	16	8
Patient 3	F	58	C5–6	Trauma	Incomplete	D	26	8
Patient 4	M	49	T6–8	Trauma	Complete	A	5	8
Patient 5	M	29	C6–7	Trauma	Complete	A	28	8
Patient 6	M	20	C6–T1	Trauma	Incomplete	B	3	8
Patient 7	M	54	T8–9	Trauma	Complete	A	17	8
Patient 8	F	63	L2	Myelitis	Complete	A	20	8
Patient 9	M	33	C3–4	Trauma	Complete	A	11	8
Patient 10	M	48	T10	Trauma	Complete	A	18	8
Patient 11	M	23	C5–6	Trauma	Complete	A	11	8
Patient 12	M	23	C6	Trauma	Complete	A	12	8
Patient 13	M	31	T6	Trauma	Complete	A	12	8
Patient 14	M	47	C4–6	Trauma	Complete	A	5	8

lumbar injury. No patient showed an interval change in neurological impairment after inclusion in the study. According to ASIA motor grade, 12 patients were grade A, 1 was grade B, and 1 patient was grade D. Patients' characteristics are shown in Table 1.

ASIA motor score

Among the 14 patients, 5 patients (patient 1, 3, 9, 11, and 12) showed motor improvement in terms of the ASIA motor score.

Patient 1, a 66-year-old male, was injured at the T12 level in a fall. After the operation and rehabilitation treatment for 8 months, there was no neurological recovery. He was paraplegic below L2 motor at baseline with an ASIA motor score of 50. After ADMSCs injection, the ASIA motor score improved to 56 at the 6-month follow-up.

Patient 3 showed improvement of motor who was ASIA grade D at the beginning. She was a 58-year-old female, injured at the C5–6 level in a fall. She was operated on and underwent rehabilitation for 26 months before this study. There was no neurological recovery over more than 3 months. She had quadriplegia at baseline, with an ASIA motor score of 73. After the stem cell therapy, her ASIA motor score was 77 at the 2-month follow-up.

Patient 9, a 33-year-old male, was injured at the C3–4 level in a bicycle accident. He was operated on and underwent rehabilitation. He was completely quadriplegic (ASIA motor score of 0) and 11 months had passed with no neurological improvement. After stem cell therapy, ASIA motor score improved to 1 at 6 months after the final intrathecal administration of ADMSCs.

Patient 11, a 24-year-old male, was injured at C5–6 in a car accident. He was operated on and underwent rehabilitation treatment. At 11 months after the injury, there

had been no further recovery for more than 3 months. His baseline ASIA motor score was 40. However, his ASIA score improved to 44 at 2 months post-transplantation.

Patient 12, a 25-year-old male, was injured in a car accident. He was injured at the C6 level and showed plegic status below C8 (ASIA motor score = 26). An operation and rehabilitation were performed but no neurological recovery was obtained. In a subjective assessment, this patient stated that at 4 months post-transplantation his back muscles seemed to be stronger so that a sitting position was more comfortable than previously. At the 2-month follow-up, his ASIA motor score was 30. Details are shown in Table 2 and 3.

Voluntary anal contraction improvement

Patient 2, a 42-year-old male, was injured at T12 in a fall. He was paraplegic and voluntary anal contraction was impossible before the study. At 1 month after stem cell transplantation, control of anal sphincters improved. Patient 7 also showed no anal voluntary contraction but 4 months after stem cell transplantation, his anal function recovered partially.

ASIA sensory score

According to the ASIA sensory scores, 10 patients showed sensory improvement (both pin prick and light touch) and 1 showed sensory deterioration. Sensory improvements were seen at L2 and caudal, including anal sensation, in patient 1, the T7–11 dermatome in patient 4, the T3–6 dermatome in patient 5, T10 and caudal, including the anus, in patient 7, the L1 and caudal in patient 8, C6–7 and T2–4 in patient 9, T10–11 in patient 10, C7–T3 in patient 12, and C2–3 in patient 14. Patient 6 was the only one who showed

Table 2 AISA motor scores

	baseline	1M	2M	4M	6M	8M
Patient 1*	50	52	54	54	56	56
Patient 2	50	50	50	50	50	50
Patient 3*	73	76	77	77	77	77
Patient 4	50	50	50	50	50	50
Patient 5	38	38	38	38	38	38
Patient 6	50	50	50	50	50	50
Patient 7	50	50	50	50	50	50
Patient 8	72	73	72	72	72	72
Patient 9*	0	0	0	0	1	1
Patient 10	50	50	50	50	50	50
Patient 11*	40	40	44	44	44	44
Patient 12*	26	27	30	30	30	30
Patient 13	50	50	50	50	50	50
Patient 14	10	10	10	10	10	10

*Patients who showed motor improvement at final follow-up assessment compare to baseline

sensory regression. Patients 2, 3, and 13 showed no interval change. Details are shown in Table 4.

MRI and electrophysiological changes

The areas of spinal damage estimated by MRI did not differ significantly before the intervention and 8 months after transplantation. The sizes of lesions showed no interval change, so there was no sign of tumorous conditions or calcification. A representative case is shown in Fig. 1. There was no significant EMG or MEP change between the baseline and post-transplantation results in any patient. However, in patient 5 (C6–7 injured with ASIA grade A), we saw definite SSEP improvements. At baseline, his right median nerve short-latency (N20P22) showed low amplitude, but at the 8-month follow-up, the amplitude increased. Furthermore, his left median nerve short-latency (N20P22) was absent at baseline, but after treatment it was restored (Fig. 2).

Adverse events

No patient developed any serious adverse event related to intrathecal ADMSC administration during the 8-month follow-up (10 months after initial transplantation). Four adverse events were observed in three patients: urinary tract infection, headache, nausea, and vomiting. Patient 11 suffered a urinary tract infection at 6 months post-transplantation. Antibiotics were administered and the infection resolved. He had a history of urinary tract infections before this study, so this event seemed unlikely to be related to the stem cell transplantation. Patient 12 complained of headache, nausea, and vomiting at 2 months post-transplantation, but after conservative treatment, the symptoms resolved. Patient 14 complained of headache at 1 month post-transplantation but this resolved over time.

Discussion

ADMSCs as an emerging source for stem cell therapy in SCI

Compared with embryonic stem cells, use of which is restricted for ethical reasons, adult stem cells have become a new source of cells for therapy. Adult stem cells can be obtained from bone marrow, umbilical cord blood, and adipose tissue.²⁴ ADMSCs, which are obtained from adipose tissue, have the ability to differentiate into various mesenchymal cells.²⁵ It is easier and less invasive to harvest ADMSCs than bone marrow stem cells.^{19,26} The material for extraction is also abundant. Furthermore, ADMSCs can be grown readily using standard tissue culture conditions and the extraction process, based on enzymes, is not complex. ADMSCs have differentiation potency to various cell lineages, so can give rise to many specialized cell types, such as smooth muscle chondrocytes, muscle cells, osteoblasts, adipose tissue, and neural cells.^{1,19,25} In this way, ADMSCs have functional similarities with other MSCs, good separation efficiency, and seem to be an attractive alternative source that can replace umbilical-cord-blood-derived MSCs and bone marrow MSCs.¹⁹

Recent studies using ADMSCs for regeneration of tissue and damaged cells have reported good results. Zhou *et al.*¹⁹ investigated whether human ADMSCs transplanted into a rat model of SCI would lead to similar or improved neurologic effects compared with human bone marrow-derived MSCs. Administration of human ADMSCs was associated with marked changes in the SCI environment, with significant increases in BDNF levels. They concluded that human ADMSCs would be more appropriate for transplant to treat SCI than human bone marrow-derived MSCs. Jeong *et al.*²⁷ designed a rat model that involved causing

Table 3 ASIA motor scores of five patients (patients 1, 3, 9, 11, and 12) who showed motor improvement at the final follow-up, compared with baseline.

	Patient 1				Patient 3				Patient 9				Patient 11				Patient 12							
	baseline	1M	2M	4M	6M	8M	baseline	1M	2M	4M	6M	8M	baseline	1M	2M	4M	6M	8M	baseline	1M	2M	4M	6M	8M
Upper extremities	No neurologic deficit																							
C5	4/4	4/4	4/4	4/4	4/4	4/4	4/4	4/4	4/4	4/4	4/4	4/4	4/4	4/4	4/4	4/4	4/4	4/4	5/5	5/5	5/5	5/5	5/5	5/5
C6	4/4	4/4	4/4	4/4	4/4	4/4	4/4	4/4	4/4	4/4	4/4	4/4	4/4	4/4	4/4	4/4	4/4	4/4	4/4	4/4	4/4	4/4	4/4	4/4
C7	4/4	4/4	4/4	4/4	4/4	4/4	4/4	4/4	4/4	4/4	4/4	4/4	4/4	4/4	4/4	4/4	4/4	4/4	4/4	4/4	4/4	4/4	4/4	4/4
C8	4/3	4/3	4/4*	4/4	4/4	4/4	4/4	4/4	4/4	4/4	4/4	4/4	4/4	4/4	4/4	4/4	4/4	4/4	4/4	4/4	4/4	4/4	4/4	4/4
T1	4/1	4/2*	4/2	4/2	4/2	4/2	4/2	4/2	4/2	4/2	4/2	4/2	4/2	4/2	4/2	4/2	4/2	4/2	3/3	3/3	3/3	3/3	3/3	3/3
Lower extremities																								
L2	0/0	1*/1*	2*/2*	2/2	2/2	2/2	4/3*	4/3	4/3	4/3	4/3	4/3	4/3	4/3	4/3	4/3	4/3	4/3	0/0	0/0	0/0	0/0	0/0	0/0
L3	0/0	0/0	0/0	0/0	1*/1*	1/1	4/3	4/4*	4/4	4/4	4/4	4/4	4/4	4/4	4/4	4/4	4/4	4/4	0/0	0/0	0/0	0/0	0/0	0/0
L4	0/0	0/0	0/0	0/0	0/0	0/0	4/4	4/4	4/4	4/4	4/4	4/4	4/4	4/4	4/4	4/4	4/4	4/4	0/0	0/0	0/0	0/0	0/0	0/0
L5	0/0	0/0	0/0	0/0	0/0	0/0	4/4	4/4	4/4	4/4	4/4	4/4	4/4	4/4	4/4	4/4	4/4	4/4	0/0	0/0	0/0	0/0	0/0	0/0
S1	0/0	0/0	0/0	0/0	0/0	0/0	4/4	4/4	4/4	4/4	4/4	4/4	4/4	4/4	4/4	4/4	4/4	4/4	0/0	0/0	0/0	0/0	0/0	0/0

C5(elbow flexors), C6(wrist extensors), C7(elbow extensors), C8(finger flexors), T1(finger abductors), L2(hip flexors), L3(knee extensors), L4(ankle dorsiflexors), L5(long toe extensors), S1(ankle plantar flexors)

*Motor improvements compare to previous evaluations

damage to a disc and transplanting human ADMSCs. At 6 weeks after transplantation therapy, they found that the reduction in regressed disc height was improved in the experimental group versus the control group and showed increased signal intensity on T2-weighted MRI. Ryu *et al.*²⁸ observed improvement in neurological function using a dog model of spinal cord injury, in which autologous ADMSCs were implanted directly into the spinal cord injury site at 1 week after spinal cord injury. They conducted a tissue examination at the 8-week follow-up and detected a neuronal cell marker from the transplanted autologous ADMSCs. Kang *et al.*¹⁷ induced oligodendrocyte progenitor cells from autologous ADMSCs and injected them via an intravenous route in a spinal cord injury model in rats. At 4–5 weeks post-transplantation, implants were found in the kidney, lung, liver, and the injured spinal cord. They explained that chemotactic material derived from the injured spinal cord attracted the stem cells to the lesion site. Park *et al.*¹⁰ and Mothe *et al.*²⁹ reported the safe use of stem cells after intrathecal administration in the spinal cord. The safety of ADMSC administration via an intravenous route in humans was also reported by Ra *et al.*³⁰

Autologous ADMSC transplantation via intrathecal injection

As explained previously, the safety and potential efficacy of autologous ADMSCs have been demonstrated. The intrathecal route also seemed to be safe for bone-marrow-derived MSC injection. However, to our knowledge, this is the first report of autologous ADMSCs transplanted intrathecally into human subjects with SCI. Among various stem cell therapy routes in spinal cord injury model, the strength of intrathecal injection is its ease of repeatability. Several previous studies used the injection method, but the optimal conditions for dosage, number, and interval of stem cell injection have not been fully established. Frolov *et al.*³¹ injected hematopoietic autologous stem cell by intrathecal route for spinal cord injured patients. The dosage for each injection was 4–8.5 × 10⁶ CD34+ cells and 1.3–1.5 × 10⁹ leukocytes. They delivered the stem cells intrathecally with lumbar puncture twice over 8-day period, with an interval of several months (usually 3–5 months) before the next doses. In a study by Danuta *et al.*³² patients with SCI were treated with autologous bone marrow nucleated cells (BMNCs) injected intravenously (3.2 × 10⁹) and intrathecally (0.5 × 10⁹) 10 weeks after the SCI and 5 rounds of MSCs every 3–4 months (1.3–3.65 × 10⁷) administered via lumbar puncture. In a case report of Ichim *et al.*,³³ they administrated

Table 4 ASIA sensory scores

		baseline	1M	2M	4M	6M	8M
Patient 1*	pin prick	78	78	80	94	96	96
	light touch	78	78	80	94	96	96
Patient 2	pin prick	78	78	78	78	78	78
	light touch	78	78	78	78	78	78
Patient 3	pin prick	112	112	112	112	112	112
	light touch	112	112	112	112	112	112
Patient 4*	pin prick	86	94	94	94	94	94
	light touch	86	94	94	94	94	94
Patient 5*	pin prick	28	28	28	32	32	32
	light touch	28	28	28	32	32	32
Patient 6 [¶]	pin prick	88	78	78	78	78	78
	light touch	88	78	78	78	78	78
Patient 7*	pin prick	70	70	70	70	70	72
	light touch	70	70	70	70	70	72
Patient 8*	pin prick	86	90	90	90	90	90
	light touch	86	90	90	90	90	90
Patient 9*	pin prick	8	8	18	18	20	20
	light touch	8	8	18	18	20	20
Patient 10*	pin prick	64	70	70	70	70	70
	light touch	64	70	70	70	70	70
Patient 11*	pin prick	40	46	76	76	76	76
	light touch	70	70	76	76	76	76
Patient 12*	pin prick	22	26	32	32	32	32
	light touch	22	26	32	32	32	32
Patient 13	pin prick	44	44	44	44	44	44
	light touch	44	44	44	44	44	44
Patient 14*	pin prick	51	53	53	53	53	53
	light touch	51	53	53	53	53	53

*Patients who showed sensory improvement at final follow-up assessment compare to baseline

¶Patient who showed sensory decline at final follow-up assessment compare to baseline

intrathecally the allogenic umbilical cord blood ex-vivo expanded CD34 and umbilical cord matrix MSC at 5 months, 8 months, and 14 months after injury. Kishk

*et al.*⁹ reported BMDSCs intrathecal injection with 5×10^6 to 10×10^6 cells every month for 6 months. In summary, the dosage for each injection varied from

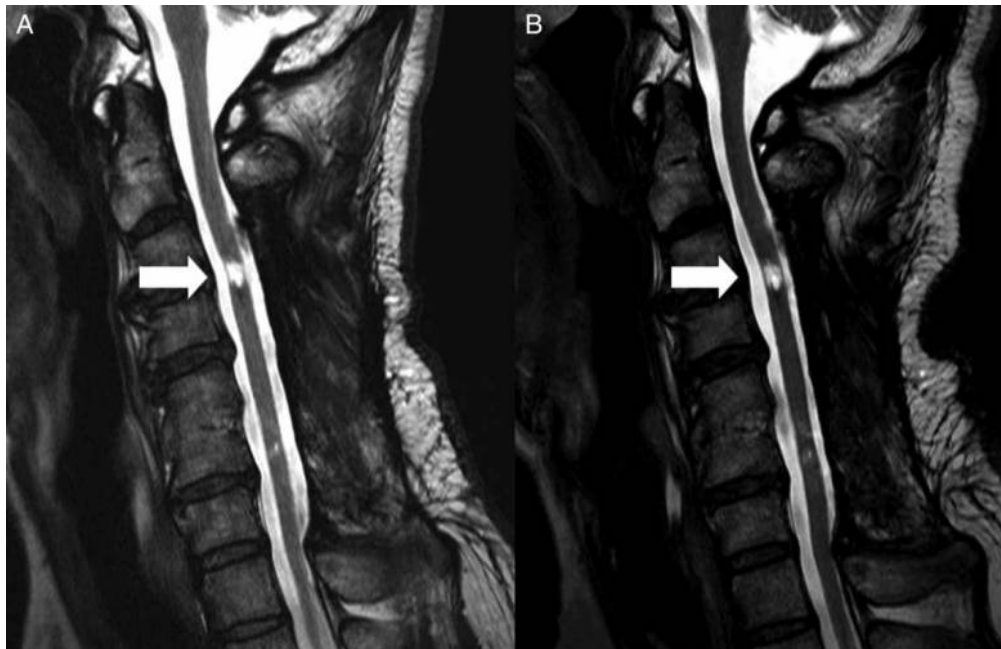

Figure 1 T2 sagittal MR image of patient 14. There was no interval change between baseline (A) and 8 months after transplantation (B).

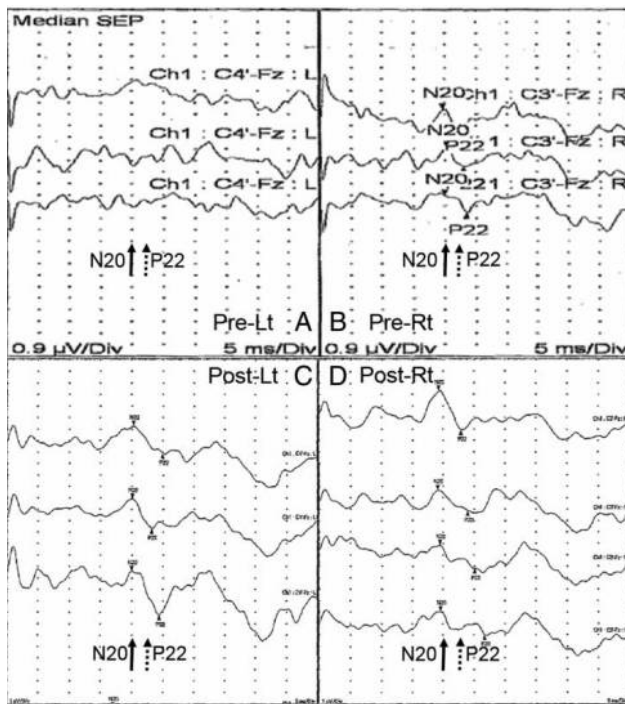


Figure 2 The dynamics of SSEP elicited by stimulation of the median nerve of patient 5. Before treatment, short-latency (N20P22) SSEP of left median nerve was absent (A), but at post-treatment 8-month follow-up, short latency (N20P22) components were restored (C). Even for the right median nerve, the amplitude of short-latency SSEP (N20P22) was abnormally low before the treatment (B) but increased after (D). Tests were performed 3 to 4 times respectively.

10^6 to 10^9 cells and the interval ranged from few days to several months. Furthermore, as we mentioned above, this is the first clinical trial of ADMSCs for SCI patients so there is no standard method for intrathecal administration. Therefore we referred to the previous literatures to decide suitable dosage, number, and interval of injection, considering safety and efficacy.

Our treatment showed good results in terms of both safety and efficacy. Objective upper or lower extremity motor improvement was seen in 5 of 14 patients. With the exception of one patient, motor recovery was seen at the 1–2-month follow-up. Intrathecal transplantation may represent a relatively direct and fast-acting route. However, most of the motor improvements were by only 1 or 2 grades in limited myotomes. Besides, even though the repeated examination of baseline neurology were stable, there are some reports of late neurologic recoveries between 1 and 5 years.^{34–36} Therefore, some of the improvements may have occurred with time instead of the treatment.

Some degree of voluntary anal contraction recovery was seen in two patients (patients 2 and 7). This was an inspiring result because it is obviously important in

terms of quality of life. Interestingly, these two patients showed no other motor recovery and only minimal sensory recovery (none for patient 2, 4 points at the 8-month follow-up for patient 7). Thus, anal function seemed to be a discrete component of recovery. Sensory recovery was seen in 71% (10/14) of patients. It was difficult to identify any trend in sensory recovery. However, sensory recovery was more likely than motor recovery after ADMSCs intrathecal injection. Also, patient 1 has shown continued recovery since the 2-month follow-up period. This suggests that sensory recovery could be prolonged and slow.

In electrophysiological tests, surprisingly one patient (patient 5) showed definite improvement in both median nerve SSEPs. He was injured at C6–7 and had upper extremity weakness and lower paraplegia. There was only sensory recovery, with no motor recovery. However, other than this patient, we saw no electrophysiological change even for the patients who had motor recovery or had sustained injuries at a similar level (C5–6). Thus, it is hard to conclude that this type of treatment could induce the change, but the possibility of some recovery due to the transplantation cannot be ruled out.

There was no interval change between baseline and MRI at 8 months post-transplantation. There was no evidence of tumors or calcification conditions to suggest that ADMSCs caused adverse effects at the lesion site. However, this interpretation was limited to there being no gross anatomical change that could be detected by MRI, given the type, amount, and route of administration of stem cells, and the follow-up period described. Also, because this was a clinical trial of actual patients, demonstrating the absence of histological changes was impossible. All of these factors should be considered when interpreting the findings.

There was no serious adverse event. A urinary tract infection in one patient seemed to be more likely due to poor personal hygiene associated with motor impairment, rather than with the stem cell injection. Headache, nausea, and vomiting could be signs of irritation due to the intrathecal injection, but these symptoms were mild and controllable.

Limitations and disadvantages

This is a pilot study to design a future optimal clinical trial for ADMSCs treatment in patients with SCI. The number of subjects and follow-up periods were limited and an objective method for the evaluation of quality of life was missing. There was no control group in this study. Practically, it is hard to build a control group because most of the patients who volunteer in such

studies express a strong preference toward being included in a treatment group. To compensate for this weak point, we conducted the study for patients with chronic SCI, who were less hopeful of neurological recovery in foreseeable future. Nevertheless, due to an insufficient number of volunteers, one patient (patient 6) had a shorter interval after impairment than the others. However this patient showed no improvements in motor but decline in sensory. Strict inclusion criteria and a blind assessment with control group are needed for further studies. In addition, non-human products such as FBS or PBS should be avoided in any part of manufacture for stem cells (because there could be potential, inherent problem) in the future.³⁷

Conclusions

This pilot study of intrathecal autologous ADMSCs transplantation in patients with chronic SCI showed that intrathecal ADMSCs transplantation has mild clinical effectiveness in some patients, regardless of the uncertain radiological and electrophysiological results. In particular, no serious adverse event occurred during intrathecal transplantation of ADMSCs. Patient selection, and the ADMSCs dosage and delivery method should be investigated further.

Disclaimer statements

Contributors 1. Conceiving and designing the study: T-HC; 2. Obtaining funding and/or ethics approval T-HC; 3. Collecting the data: JWH; 4. Analysing the data: JWH; 5. Interpreting the data: JWH; 6. Writing the article in whole or in part: JWH, D-HP; 7. Revising the article: J-BL.

Funding None.

Conflicts of interest This research was supported financially by Bukwang Pharma. Co., Seoul, Korea. The manuscript submitted does not contain information about medical device(s)/drug(s). No benefits in any form have been or will be received from a commercial party related directly or indirectly to the subject of this manuscript. The authors declare that they have no competing interests.

Ethics approval This phase I study of autologous ADMSC intrathecal therapy for SCI was approved by the Korean Food and Drug Administration (Investigational New Drug Application no. 201005033) and the Korea University Anam Hospital (Seoul, Korea) Institutional Review Board (No. ED 11144).

References

- Zhao Y, Jiang H, Liu XW, Chen JT, Xiang LB, Zhou DP. Neurogenic differentiation from adipose-derived stem cells and application for autologous transplantation in spinal cord injury. *Cell Tissue Bank* 2014 Oct 22. [Epub ahead of print].
- Bracken MB, Shepard MJ, Hellenbrand KG, Collins WF, Leo LS, Freeman DF, *et al.* Methylprednisolone and neurological function 1 year after spinal cord injury. Results of the National Acute Spinal Cord Injury Study. *J Neurosurg* 1985;63(5):704–13.
- Bracken MB, Shepard MJ, Collins WF, Holford TR, Young W, Baskin DS, *et al.* A randomized, controlled trial of methylprednisolone or naloxone in the treatment of acute spinal-cord injury. Results of the Second National Acute Spinal Cord Injury Study. *N Engl J Med* 1990;322(20):1405–11.
- Bracken MB, Shepard MJ, Holford TR, Leo-Summers L, Aldrich EF, Fazl M, *et al.* Administration of methylprednisolone for 24 or 48 hours or tirilazad mesylate for 48 hours in the treatment of acute spinal cord injury. Results of the Third National Acute Spinal Cord Injury Randomized Controlled Trial. *National Acute Spinal Cord Injury Study. JAMA* 1997;277(20):1597–604.
- Short DJ, El Masry WS, Jones PW. High dose methylprednisolone in the management of acute spinal cord injury—a systematic review from a clinical perspective. *Spinal Cord* 2000;38(5):273–86.
- Coutts M, Keirstead HS. Stem cells for the treatment of spinal cord injury. *Exp Neurol* 2008;209(2):368–77.
- Kim BG, Hwang DH, Lee SI, Kim EJ, Kim SU. Stem cell-based cell therapy for spinal cord injury. *Cell Transplant* 2007;16(4):355–64.
- Pal R, Venkataramana NK, Bansal A, Balaraju S, Jan M, Chandra R, *et al.* Ex vivo-expanded autologous bone marrow-derived mesenchymal stromal cells in human spinal cord injury/paraplegia: a pilot clinical study. *Cytotherapy* 2009;11(7):897–911.
- Kishk NA, Gabr H, Hamdy S, Afifi L, Abokresha N, Mahmoud H, *et al.* Case control series of intrathecal autologous bone marrow mesenchymal stem cell therapy for chronic spinal cord injury. *Neurorehabil Neural Repair* 2010;24(8):702–8.
- Park HC, Shim YS, Ha Y, Yoon SH, Park SR, Choi BH, *et al.* Treatment of complete spinal cord injury patients by autologous bone marrow cell transplantation and administration of granulocyte-macrophage colony stimulating factor. *Tissue Eng* 2005;11(5–6):913–22.
- Cristante AF, Barros-Filho TE, Tatsui N, Mendrone A, Caldas JG, Camargo A, *et al.* Stem cells in the treatment of chronic spinal cord injury: evaluation of somatosensitive evoked potentials in 39 patients. *Spinal Cord* 2009;47(10):733–8.
- Parr AM, Tator CH, Keating A. Bone marrow-derived mesenchymal stromal cells for the repair of central nervous system injury. *Bone Marrow Transplant* 2007;40(7):609–19.
- Bianco P, Riminucci M, Gronthos S, Robey PG. Bone marrow stromal stem cells: nature, biology, and potential applications. *Stem Cells* 2001;19(3):180–92.
- Chan TM, Harn HJ, Lin HP, Chiu SC, Lin PC, Wang HI, *et al.* The use of ADSCs as a treatment for chronic stroke. *Cell Transplant* 2014;23(4–5):541–7.
- Jeon D, Chu K, Lee ST, Jung KH, Ban JJ, Park DK, *et al.* Neuroprotective effect of a cell-free extract derived from human adipose stem cells in experimental stroke models. *Neurobiol Dis* 2013;54:414–20.
- Gutierrez-Fernandez M, Rodriguez-Frutos B, Otero-Ortega L, Ramos-Cejudo J, Fuentes B, Diez-Tejedor E. Adipose tissue-derived stem cells in stroke treatment: from bench to bedside. *Discov Med* 2013;16(86):37–43.
- Kang SK, Shin MJ, Jung JS, Kim YG, Kim CH. Autologous adipose tissue-derived stromal cells for treatment of spinal cord injury. *Stem Cells Dev* 2006;15(4):583–94.
- Kolar MK, Kingham PJ, Novikova LN, Wiberg M, Novikov LN. The therapeutic effects of human adipose-derived stem cells in a rat cervical spinal cord injury model. *Stem Cells Dev* 2014;23(14):1659–74.
- Zhou Z, Chen Y, Zhang H, Min S, Yu B, He B, *et al.* Comparison of mesenchymal stromal cells from human bone marrow and adipose tissue for the treatment of spinal cord injury. *Cytotherapy* 2013;15(4):434–48.

- 20 Menezes K, Nascimento MA, Goncalves JP, Cruz AS, Lopes DV, Curzio B, *et al.* Human mesenchymal cells from adipose tissue deposit laminin and promote regeneration of injured spinal cord in rats. *PLoS One* 2014;9(5):e96020.
- 21 Ganey T, Hutton WC, Moseley T, Hedrick M, Meisel HJ. Intervertebral disc repair using adipose tissue-derived stem and regenerative cells: experiments in a canine model. *Spine (Phila Pa 1976)* 2009;34(21):2297–304.
- 22 Hoogendoorn RJ, Lu ZF, Kroeze RJ, Bank RA, Wuisman PI, Helder MN. Adipose stem cells for intervertebral disc regeneration: current status and concepts for the future. *J Cell Mol Med* 2008;12(6a):2205–16.
- 23 Yoshikawa T, Ueda Y, Miyazaki K, Koizumi M, Takakura Y. Disc regeneration therapy using marrow mesenchymal cell transplantation: a report of two case studies. *Spine (Phila Pa 1976)* 2010;35(11):E475–80.
- 24 Volarevic V, Bojic S. Stem cells as new agents for the treatment of infertility: current and future perspectives and challenges. *Biomed Res Int.* 2014;2014:507234.
- 25 Yamada T, Akamatsu H, Hasegawa S, Yamamoto N, Yoshimura T, Hasebe Y, *et al.* Age-related changes of p75 neurotrophin receptor-positive adipose-derived stem cells. *J Dermatol Sci* 2010;58(1):36–42.
- 26 Arboleda D, Forostyak S, Jendelova P, Marekova D, Amemori T, Pivonkova H, *et al.* Transplantation of predifferentiated adipose-derived stromal cells for the treatment of spinal cord injury. *Cell Mol Neurobiol* 2011;31(7):1113–22.
- 27 Jeong JH, Lee JH, Jin ES, Min JK, Jeon SR, Choi KH. Regeneration of intervertebral discs in a rat disc degeneration model by implanted adipose-tissue-derived stromal cells. *Acta Neurochir (Wien)* 2010;152(10):1771–7.
- 28 Ryu HH, Lim JH, Byeon YE, Park JR, Seo MS, Lee YW, *et al.* Functional recovery and neural differentiation after transplantation of allogenic adipose-derived stem cells in a canine model of acute spinal cord injury. *J Vet Sci* 2009;10(4):273–84.
- 29 Mothe AJ, Kulbatski I, Parr A, Mohareb M, Tator CH. Adult spinal cord stem/progenitor cells transplanted as neurospheres preferentially differentiate into oligodendrocytes in the adult rat spinal cord. *Cell Transplant* 2008;17(7):735–51.
- 30 Ra JC, Shin IS, Kim SH, Kang SK, Kang BC, Lee HY, *et al.* Safety of intravenous infusion of human adipose tissue-derived mesenchymal stem cells in animals and humans. *Stem Cells Dev* 2011;20(8):1297–308.
- 31 Frolov AA, Bryukhovetskiy AS. Effects of hematopoietic autologous stem cell transplantation to the chronically injured human spinal cord evaluated by motor and somatosensory evoked potentials methods. *Cell Transplant* 2012;21(Suppl 1):S49–55.
- 32 Danuta J, Olga M, Anna W, Stanislaw K, Marcin M. Continuous improvement after multiple mesenchymal stem cells transplantations in a patient with complete spinal cord injury. *Cell Transplant* 2015;24(4):661–72.
- 33 Ichim TE, Solano F, Lara F, Paris E, Ugalde F, Rodriguez JP, *et al.* Feasibility of combination allogeneic stem cell therapy for spinal cord injury: a case report. *Int Arch Med* 2010;3:30.
- 34 Kirshblum S, Millis S, McKinley W, Tulskey D. Late neurologic recovery after traumatic spinal cord injury. *Arch Phys Med Rehabil* 2004;85(11):1811–7.
- 35 Wirth B, van Hedel HJ, Komater B, Dietz V, Curt A. Changes in activity after a complete spinal cord injury as measured by the Spinal Cord Independence Measure II (SCIM II). *Neurorehabil Neural Repair* 2008;22(3):279–87.
- 36 Steeves JD, Lammertse DP, Kramer JLK, Kleitman N, Kleitman N, Kalsi-Ryan S, *et al.* Outcome measures for acute/subacute cervical sensorimotor complete (AIS-A) spinal cord injury during a phase 2 clinical trial. *Top Spinal Cord Inj Rehabil* 2012;18(1):1–14.
- 37 Selvaggi TA, Walker RE, Fleisher TA. Development of antibodies to fetal calf serum with arthus-like reactions in human immunodeficiency virus-infected patients given syngeneic lymphocyte infusions. *Blood* 1997;89(3):776–9.